



ELSEVIER



# Anatomical evaluation of the internal mammary vessels based on magnetic resonance imaging (MRI)<sup>☆, ☆ ☆</sup>

Stefania Tuinder<sup>b,\*</sup>, Rieky Dikmans<sup>b</sup>, Robert-Jan Schipper<sup>a,c</sup>,  
Marc Lobbes<sup>a</sup>, Carla Boetes<sup>a</sup>, Wouter Peeters<sup>b</sup>, René Van Der Hulst<sup>b</sup>

<sup>a</sup> Department of Radiology, Maastricht University Medical Centre (MUMC+), Maastricht, The Netherlands

<sup>b</sup> Department of Plastic Surgery, Maastricht University Medical Centre (MUMC+), P. Debyelaan 25, 6202AZ Maastricht, The Netherlands

<sup>c</sup> Department of Surgery, Maastricht University Medical Centre (MUMC+), Maastricht, The Netherlands

Received 16 December 2011; accepted 26 April 2012

## KEYWORDS

Internal mammary vessels;  
Breast reconstruction;  
Intercostal space;  
Rib-sparing approach

**Summary** *Introduction:* The rib-sparing technique to access the internal mammary vessels for microanastomosis is the current practice in our hospital nowadays. This study is performed to analyse the best intercostal space to expose those vessels.

*Patients and methods:* Magnetic resonance imaging (MRI) of the chest wall of 133 women was evaluated. The Schwabegger classification (representing the anatomical variation), the intercostal space between ribs two, three and four, and the surface of the internal mammary artery and veins in the second and third intercostal space were determined on multiplanar reconstructed T2-weighted images.

*Results:* In more than half of the cases, the anatomy followed Schwabegger variation two; one lateral artery and one medial vein were symmetrical. If a second vein was present, the bifurcation was most commonly in the third intercostal space. The second intercostal space above the mammary vessels was significantly wider than the third one. The surface of the artery and vein(s) was significantly larger in the second intercostal space.

*Conclusion:* In most clinical situations, the second intercostal space is most likely the best approach to the internal mammary vessels for microanastomosis using a rib-sparing technique because of wider intercostal space and larger artery and vein.

© 2012 British Association of Plastic, Reconstructive and Aesthetic Surgeons. Published by Elsevier Ltd. All rights reserved.

<sup>\*</sup> The work was presented at the following meetings: NVPC Meeting April 2011 (National Meeting of the Dutch Society of Plastic Surgery), WSRM 2011 (Biannual Meeting of the World Society of Reconstructive Microsurgery), Meeting of the Italian Society of Microsurgery 2011.

<sup>\*\*</sup> The work should be attributed to MUMC+ Maastricht (NL).

\* Corresponding author. Tel.: +31 43 3877481.

E-mail addresses: [nervofaciale@yahoo.it](mailto:nervofaciale@yahoo.it), [s.tuinder@mumc.nl](mailto:s.tuinder@mumc.nl) (S. Tuinder).

In 1983, Shaw described the use of the mammary artery and vein(s) as recipient vessels in breast reconstruction.<sup>1</sup> He used the vessels in the fifth intercostal space reporting that the internal mammary vein was very small. He could use it as a recipient vessel in only three of the eight cases.

In 1994, Feller advised not to use the mammary vessels because the vein is often not suitable for micro-anastomosis.<sup>2</sup> In 1996, Dupin reported a series of 110 consecutive cases of breast reconstruction with a successful flap transfer in 99%<sup>3</sup> using the internal mammary artery and vein. Based on clinical experience and the data reported by Clark,<sup>4</sup> Dupin advised to isolate the mammary vessels under the third rib.<sup>3</sup> Despite the excellent and reliable exposure, the removal of part of the rib has been associated with postoperative local pain, long-term tenderness and sometimes contour deformities of the chest wall.<sup>8,9</sup>

Although perforators of the mammary artery and vein as recipient vessels are an alternative, this is not always possible.<sup>10,11</sup>

In 2008, Parrett<sup>5</sup> described a series of 74 flaps for breast reconstruction using the rib-sparing technique for internal mammary vessel exposure without increasing the complication rate. The vessels were exposed in the third intercostal space.

In 2009, Sacks<sup>6</sup> presented 100 consecutive cases of breast reconstruction with the rib-sparing technique; also, in these cases, the third intercostal space was used. In 90%, no rib cartilage was removed.

In 2011, Malata<sup>7</sup> suggests several recommendations for successful microvascular abdominal flap breast reconstruction using the total rib preservation technique for exposure of the internal mammary vessels. He switches from the exposure of the vessels in the third and fourth intercostal space to the second one because it is easier clinically. With this study, we would like to objectively describe the intercostal spaces to expose the internal mammary vessels with a rib-sparing technique and to identify the advantages and disadvantages in selecting the second or the third intercostal space.

## Materials and methods

In the period August–November 2010, 294 breast magnetic resonance imagings (MRIs) were performed in 289 patients in our institution. Exclusion criteria were male sex, history of breast surgery, neo-adjuvant chemotherapy and patients with bilateral breast cancer. In cases where there were multiple MRIs in one patient, only the first MRI was included. A single radiologist independently considered all MRIs for inclusion. A total of 125 MRIs were excluded (Table 1). During image analysis, an additional 36 MRIs were excluded because the internal mammary artery and vein(s) were inadequately depicted, resulting in 133 patients whose MRIs were included.

MRIs of the chest wall of 133 women were evaluated.

Images were acquired on a Philips 1.5 T Intera MRI scanner (Philips Healthcare, Best, the Netherlands) using a dedicated 16-channel breast coil. Measurements were performed on a three-dimensional, T2-weighted turbo spin echo sequence, which is part of our standard MR mammography protocol. Imaging parameters were TR

**Table 1** Exclusion criteria MRI.

Patient exclusion reason	<i>n</i>	%
BCT in history	61	38
Mastectomy in history	18	11
Oncoplastic reconstruction	17	11
NAC	4	2
Bilateral breast cancer	1	1
History of benign breast surgery	5	3
Other	19	12
Insufficient MR image quality	36	22
<b>Total</b>	<b>161</b>	<b>100</b>

Patient exclusion reason. BCT = Breast Conservative Therapy. NAC = Neo-Adjuvant Chemotherapy. MRI: Magnetic Resonance Imaging.

2000 ms, TE 205 ms, slice thickness 1 mm, field-of-view 280 × 338, reconstructed matrix 352, resulting in a reconstructed in-plane resolution of 0.97 × 0.97 mm.

Two independent and equally experienced clinical physicians reviewed the MRI scans blinded. They scored three different outcomes.

First, the Schwabegger classification was evaluated: it provides four different types of anatomical variation of the internal mammary artery and vein (Figure 1). We added another fifth classification for all those anatomical variations not included in the Schwabegger classification.

Second, the intercostal space between ribs two, three and four was measured with a line measurement technique just above the artery (Figure 2).

Finally, internal mammary artery and vein surfaces were measured in the second and third intercostal space exactly beneath the upper costal edge with a free-hand technique (Figure 3).

Surface refers to the cross-sectional area of the outer contour of a vessel. The surface of the vessels was then translated in diameter measurements to make the results easier to understand from a clinical point of view.

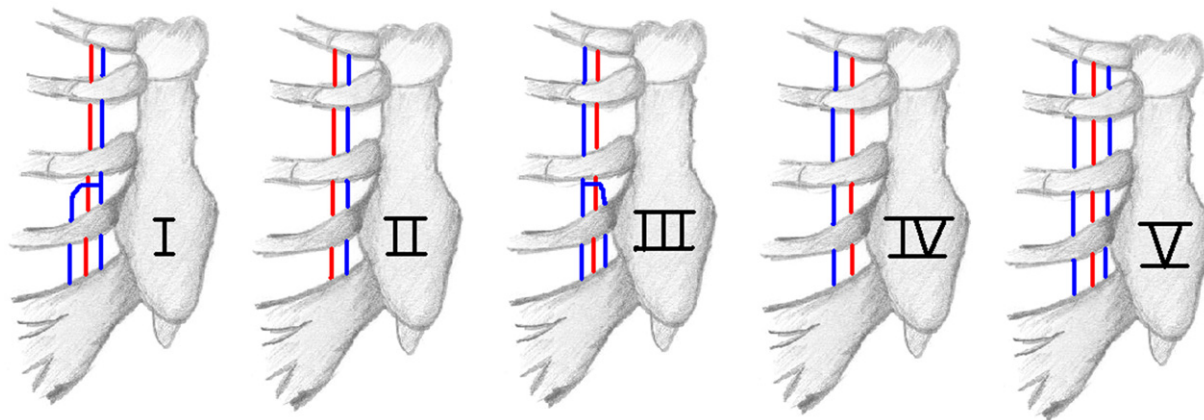
All analyses were performed using SPSS 18.0 (fabricant, land, etc). Interobserver variation in measurements was presented as the kappa value. To measure artery and vein surface we used the Schwabegger anatomical variation II (*n* = 92). Differences between groups, such as intercostal space and surface, were assessed using independent-samples *t*-test for continuous variables.

## Results

The anatomical variation outcome was similar for both observers. The intraobserver kappa analyses were good for both sides (0.73 for the left and 0.72 for the right side). We observed that variation II is more frequently present (left mean 75%, right mean 72%), followed by variation IV, I, V and III (Table 2).

The second intercostal space was significantly larger than the third intercostal space on the right (4.4 mm) and on the left side (4.5 mm) (Table 3).

There was a significant difference in the artery surface between intercostal spaces two and three. On the left side,



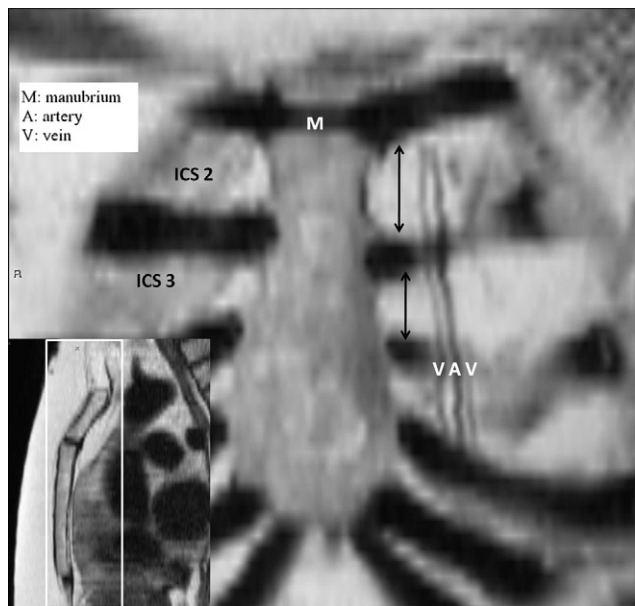
**Figure 1** Schwabegger classification of anatomic variation of mammary vessels. Variation V is added to the original Schwabegger classification. The mammary artery is the red line en the mammary veins are the blue lines.

the artery surface in the second intercostal space was significantly larger ( $0.6 \text{ mm}^2$ ) than the artery surface in the third one ( $p < 0.001$ ). On the right side, the artery surface in the second intercostal space was significantly larger ( $0.7 \text{ mm}^2$ ) ( $p < 0.001$ ). After translating the mean of the artery surface difference ( $0.7 \text{ mm}^2$ ) into a more clinical value, the diameter, the difference was 0.2 mm between intercostal space two and three. The artery diameter in the second intercostal space is 18% larger.

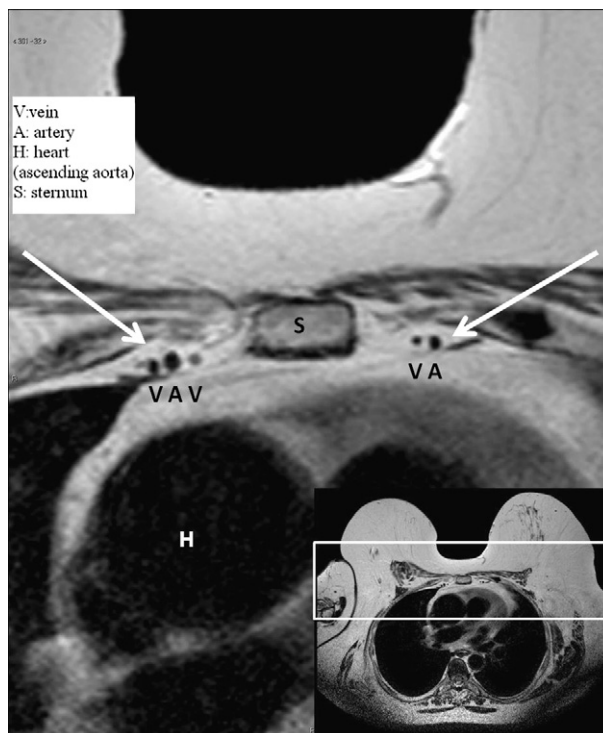
A significant difference in vein surface between intercostal spaces two and three was also observed. On the left and right sides, the vein surface in the second intercostal space was significantly ( $p < 0.001$ ) larger ( $0.5 \text{ mm}^2$ ). The difference in diameter was 0.2 mm between intercostal spaces two and three. The vein diameter in the second intercostal space was 18% larger (Table 4).

### Discussion

Since breast reconstruction with the transverse rectus abdominis myocutaneous (TRAM) flap was first described by Hartrampf in 1982,<sup>12</sup> the reduction of the morbidity of the operation has become the goal: the deep inferior epigastric perforator flap is the result of this process decreasing donor-site morbidity at the abdominal region. The rib-sparing technique reduces the donor-site morbidity at the level of the recipient vessels.



**Figure 2** Coronal reconstruction of MRI images. The intercostal space between ribs two, three and four was measured with a line measurement technique.



**Figure 3** Transverse reconstruction of MRI images. Internal mammary artery and veins surfaces were measured in the second and third intercostal space exactly beneath the upper costal edge with a free-hand technique.

**Table 2** Anatomical variation.

Classification (%)	Left		Right	
	Observer	Observer	Observer	Observer
	1	2	1	2
1	5.6	5.6	6.3	4.9
2	73.6	75.7	69.9	75
3	2.1	0.7	0.7	0
4	15.3	15.3	18.9	16.7
5	3.5	2.8	4.2	3.5
kappa analysis	0.72		0.73	

Malata et al.<sup>7</sup> already discussed the tips, advantages and disadvantages of a rib-sparing approach to the mammary vessels; they advise

1. to keep the intercostal muscle excision medial to 3 cm,
2. to transfix the vein caudally if possible,
3. to judiciously remove the costal cartilage to optimise exposure and facilitate anastomosis or, in some cases,
4. to sacrifice the rib cartilage if really necessary,
5. to keep the intercostal nerve above the vessels,
6. to lose approximation of pectoralis muscle split,
7. to use the standard anastomotic suture technique and
8. to use long-handled microvascular instruments.

They conclude recommending this technique. They started with isolation of the mammary vessels in the third intercostal space and in the last cases of their series they isolated the vessels in the second intercostal one more and more because in the third intercostal space they sometimes had to remove a part of a rib to have good access to the anastomosis. Moreover, in some cases, it was observed that the vein splits into two branches under the third rib giving two smaller veins in the third intercostal space.

We analysed the characteristics of the second and third intercostal space with MRI. The MRIs were made during staging of patients with breast cancer; in the future, a preoperative MRI could be used to add information from also above the mammary vessels and intercostal spaces.

The second intercostal space is mean 4.4 mm (29%) wider than the third one, giving better access to the blood vessels. In the second intercostal space 138 veins were found and 146 in the third one. Therefore, we conclude that in the most cases of variation III and I of Schwabegger the vein divides under the third rib confirming the study by Malata. As a consequence, if the vein divides, usually in the intercostal space 2 only one vein will be present and in the intercostal space 3 two veins will be present. It may be better to use the third intercostal space in case two venous anastomoses are needed. Hanasono demonstrated that two venous anastomoses are not decidedly better than one

**Table 3** Intercostal space (ICS).

ICS (mm)	ICS 2	ICS 3	Difference (95%)	<i>P</i> < 0.005
Right	19.87	15.49	4.37 [3.79–4.95]	<0.001
Left	19.97	15.46	4.5 [3.98–5.03]	<0.001

**Table 4** Surface.

	ICS 2	ICS 3	Difference (95%)	<i>P</i> < 0.005
<b>Surface artery (mm<sup>2</sup>)</b>				
Right	4.59	3.85	0.74 [0.59–0.89]	<0.001
Left	4.19	3.57	0.61 [0.49–0.73]	<0.001
<b>Surface vein (mm<sup>2</sup>)</b>				
Right	3.67	3.14	0.53 [0.37–0.68]	<0.001
Left	3.37	2.83	0.53 [0.41–0.66]	<0.001
Artery, ICS 2 – ICS 3 = 0.68 mm <sup>2</sup> /π → Δ0.2 mm (+18%).				
Vein, ICS 2 – ICS 3 = 0.53 mm <sup>2</sup> /π → Δ0.2 mm (+18%).				

because venous blood velocity is significantly greater after a single venous anastomosis than in either of the two veins when two venous anastomoses are performed.<sup>13</sup>

The diameter of the artery is mean 0.2 mm (18%) and of the vein mean 0.2 mm (18%) larger in the second than in the third intercostal space. The surface and then the mean diameter of the vessels were calculated only for patients with Schwabegger classification II because statistical analysis had to be performed. The number of patients with Schwabegger classification I, III, IV and V are not enough to perform a statistical analysis for each group. On the other hand, the inclusion of cases with classification I and III will only support our data more because the two veins in the intercostal space 3 singularly always have a smaller diameter than the single vein in the intercostal space 2, but this can be considered as a confounding element in the statistical analysis.

To determine the best approach to the mammary vessels more details have to be clinically considered.

First of all, the use of mammary vessels as recipient vessels is widely accepted, although they will not be always suitable anymore in the future for coronary bypass surgery. Greer-Bayramoglu et al.<sup>14</sup> demonstrated that only by using the left mammary artery in the fourth intercostal space distally, the length of the mammary artery preserved will be enough for future bypass surgery. However, at the fourth intercostal space level distally the mammary vein is often not suitable for adequate anastomosis.<sup>1–4</sup> As a consequence, the use of the second or third intercostal space will not change the suitability of the vessels for future bypass surgery.

Second, if the flap selected for breast reconstruction has a short pedicle like a TMG (transverse myocutaneous gracilis) flap or a Sc-GAP (septocutaneous gluteal artery perforator) flap, the second intercostal space can be too proximal to put the flap at the right height to obtain a well-shaped breast without tension on the pedicle.

Third, the second intercostal space can be difficult to reach in a prophylactic, nipple-sparing mastectomy with an incision at the inframammary fold.

In those cases, we will advise to select the third intercostal space sacrificing only a part of the second rib to have a better exposure to the mammary vessels. Preoperative MRI evaluation might help in the planning of the procedure.

## Conclusion

We conclude that, in most of the cases, the second intercostal space, from an anatomical point of view, is the most

suitable for a rib-sparing approach of the mammary vessels for microanastomosis because it is significantly wider and it has significantly larger vessels (artery and vein) than the third one; moreover, if a division of the vein occurs this is distally to the second intercostal space. The clinical situation always has to be considered.

### Conflict of interest

None.

### Funding

None.

### References

1. Shaw WW. Breast reconstruction by superior gluteal microvascular free flaps without silicone implants. *Plast Reconstr Surg* 1983;**72**:490.
2. Feller AM. Free TRAM: results and abdominal wall function. *Clin Plast Surg* 1994;**21**:223.
3. Dupin CL, Allen R, Glass CA, Bunch R. The internal mammary artery and vein as recipient site for free-flap breast reconstruction: a report of 110 consecutive cases. *Plast Reconstr Surg* 1996;**98**(4):685–9.
4. Clark CP, Pittman CE, Rohrich RJ. An anatomical study of the internal mammary artery and vein. In: Presented at the Annual Meeting of the American Society for Reconstructive Microsurgery, Marco island; 1995.
5. Parrett B, Caterson SA, Tobias A, Lee BT. The rib-sparing technique for internal mammary vessel exposure in microsurgical breast reconstruction. *Ann Plast Surg* 2008;**60**(3):241–3.
6. Sacks JM, Chang DW. Rib-sparing internal mammary vessel harvest for microvascular breast reconstruction in 100 consecutive cases. *Plast Reconstr Surg* 2009;**123**(5):1403–1407.
7. Malata CM, Moses M, Mickute Z, Di Candia M. Tips for successful microvascular abdominal flap reconstruction utilizing the “total rib preservation” technique for internal mammary vessel exposure. *Ann Plast Surg* 2011;**66**(1):36–42.
8. Levine JL, Allen RJ, Khoobei K. Opened book technique for accessing the internal mammary vessels for microanastomosis. *J Reconstr Microsurg* 2006:22.
9. Schoeller T, Schubert HM, Wechselberger G. Rib cartilage replacement to prevent contour deformity after internal mammary vessel access. *J Plast Reconstr Aesthet Surg* 2008;**61**:464–6.
10. Guzzetti T, Thione A. A successful breast reconstruction with a perforator to deep inferior epigastric perforator flap. *Ann Plast Surg* 2001;**46**:641–3.
11. Munoz AM, Ishida LH, Montag E, et al. Perforator flap breast reconstruction using internal mammary perforator branch as a recipient site: an anatomical and clinical analysis. *Plast Reconstr Surg* 2004;**114**(1):62–8.
12. Hartrampf CR, Schefflan M, Black PW. Breast reconstruction with a transverse abdominal island flap. *Plast Reconstr Surg* 1982;**69**:216–25.
13. Hanasono MM, Kocak E, Ogunleye O, Hartley CJ, Miller MJ. One versus two venous anastomoses in microvascular free flap surgery. *Plast Reconstr Surg* 2010 Nov;**126**(5):1548–57.
14. Greer-Bayramoglu RJ, Chu MW, Fortin AJ. Feasibility of internal mammary vessel use in breast reconstruction versus coronary artery bypass surgery: an anatomic, cadaveric evaluation. *Plast Reconstr Surg* 2011 May;**127**(5):1783–9.